

Laparoscopic hepaticojejunostomy and gastrojejunostomy for palliative treatment of pancreatic head cancer in 48 patients

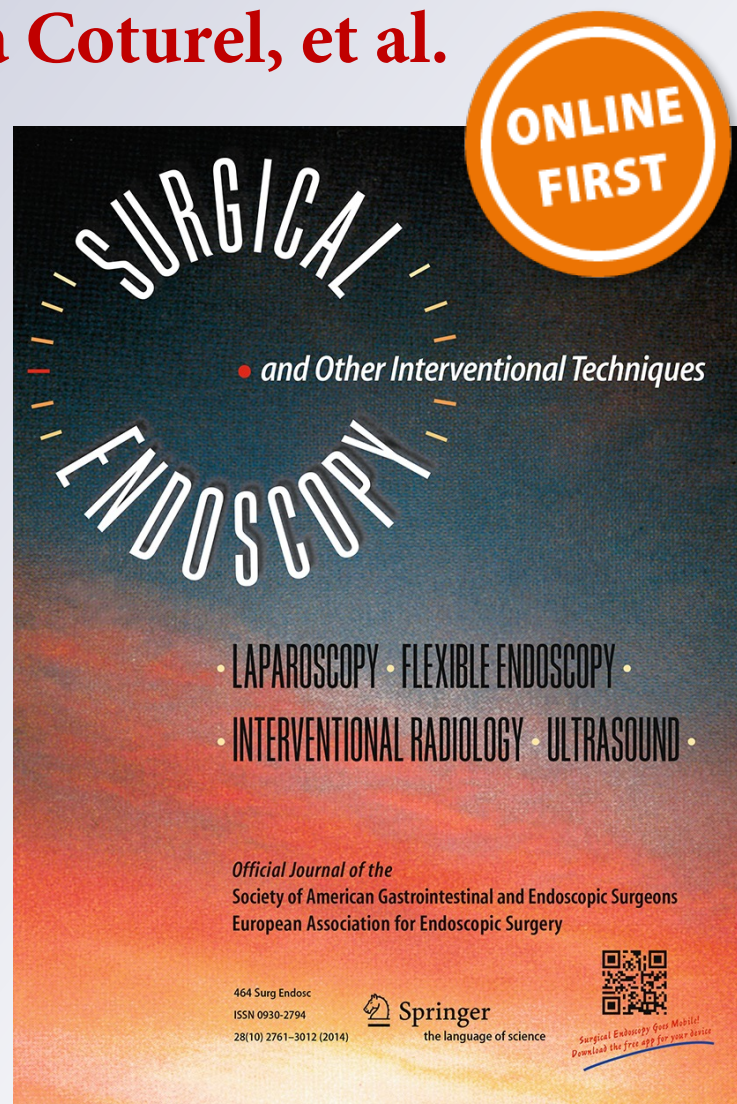
**Gustavo Kohan, Carlos G. Ocampo,
Hugo I. Zandalazini, Roberto
Klappenbach, Federico Yazyi, Ornella
Ditulio, Adelina Coturel, et al.**

Surgical Endoscopy

And Other Interventional Techniques
Official Journal of the Society of
American Gastrointestinal and
Endoscopic Surgeons (SAGES) and
European Association for Endoscopic
Surgery (EAES)

ISSN 0930-2794

Surg Endosc
DOI 10.1007/s00464-014-3894-y



Your article is protected by copyright and all rights are held exclusively by Springer Science +Business Media New York. This e-offprint is for personal use only and shall not be self-archived in electronic repositories. If you wish to self-archive your article, please use the accepted manuscript version for posting on your own website. You may further deposit the accepted manuscript version in any repository, provided it is only made publicly available 12 months after official publication or later and provided acknowledgement is given to the original source of publication and a link is inserted to the published article on Springer's website. The link must be accompanied by the following text: "The final publication is available at link.springer.com".

Laparoscopic hepaticojejunostomy and gastrojejunostomy for palliative treatment of pancreatic head cancer in 48 patients

Gustavo Kohan · Carlos G. Ocampo · Hugo I. Zandalazini · Roberto Klappenbach · Federico Yazzi · Ornella Ditulio · Adelina Coturel · Carlos Canullán · Luis T. Chiappetta Porras · Juan Alvarez Rodriguez

Received: 23 May 2014 / Accepted: 8 September 2014
© Springer Science+Business Media New York 2014

Abstract

Introduction Approximately 80 % of patients with pancreatic cancer are not candidates for curative resection at the time of diagnosis. The objective of this study is to show that although endoscopic treatment is the standard palliation, surgical laparoscopic treatment is both feasible and effective for these patients.

Materials and methods Preoperative resectability was evaluated by dynamic contrast-enhanced computed tomography scans. Endoscopic palliation was the first choice for patients with metastatic disease and for patients with locally advanced pancreatic cancer with bad performance status. Laparoscopic surgical palliation was indicated for patients with jaundice and locally advanced pancreatic cancer (elective palliation) and for patients with jaundice with metastatic disease and failure in the endoscopic/percutaneous treatment (necessary palliation). Elective palliation consisted of Roux-en-Y hepaticojejunostomy and gastrojejunostomy and necessary palliation consisted of laparoscopic hepaticojejunostomy alone.

Results A total of 48 patients received laparoscopic surgical palliation. Morbidity rate was 33.3 % and mortality was 2.08 %. There was no need for late surgeries in any of the patients.

Conclusion Surgical laparoscopic palliation is a feasible treatment option for locally advanced pancreatic cancer.

Even though metallic stents are still the best palliation method for patients with systemic disease, if stents fail, the laparoscopic approach is a viable treatment.

Keywords Unresectable pancreatic cancer · Laparoscopic palliation · Laparoscopic hepaticojejunostomy · Laparoscopic double derivation

Pancreatic cancer is the fourth leading cause of cancer-related death in Western society, with an estimated 45,220 new cases diagnosed in the United States in 2010 [1]. Approximately 80 % of these patients are not candidates for curative resection at the time of diagnosis, and 30 % of them will present a non-metastatic locally advanced disease [2]. At this stage of the disease, the estimated survival is more than 8 months and may be more than 1 year with new oncologic treatments [3].

Most pancreatic tumors are located in the head and cause obstructive jaundice, and approximately 20 % of these patients will also develop duodenal obstruction [4]. In this context of advanced disease, symptom palliation and oncologic treatment are the main objectives in dealing with this pathology. Traditionally, palliation of pancreatic cancer is divided into mini-invasive (endoscopic or percutaneous) or surgery (open surgery). Endoscopic or percutaneous palliation has the initial advantages of rapid recovery, low morbidity rates, and shorter hospital stays while disadvantages are stent obstruction [5], duodenal obstruction, higher number of reinterventions, and shorter hospital-free survival rate. Conventional surgical palliation (hepaticojejunostomy and gastrojejunostomy or double bypass) presents, conversely, higher postoperative morbidity but long-term, long-lasting palliation [6].

In order to combine the immediate advantages of mini-invasive procedures with the long-term palliation of

G. Kohan (✉) · C. G. Ocampo · H. I. Zandalazini · R. Klappenbach · F. Yazzi · O. Ditulio · A. Coturel · C. Canullán · L. T. C. Porras · J. A. Rodriguez
Department of Surgery, Hospital Cosme Argerich, University of Buenos Aires, José Juan Biedma 773, CABA, Buenos Aires, Argentina
e-mail: gustavokohan@yahoo.com.ar

surgical bypass, we propose laparoscopic bypass as an alternative for patients with local unresectability or with systemic disease when endoscopic/percutaneous palliation fails. The objective of this study is to show that surgical laparoscopic treatment is both feasible and effective for these patients.

Materials and methods

Study design

This single-center prospective and observational study was performed at the Cosme Argerich Hospital, in Buenos Aires, Argentina, a tertiary care, university-affiliated public hospital, specialized in hepato-pancreato-biliary surgery. All procedures, including the patient's or responsible relative's written informed consent to be included in the study, were conducted in accordance with the recommendations of the Cosme Argerich Hospital's Ethics Committee. The study protocol was approved on June 23, 2007.

There are no possible conflicts of interest declared.

Population

All patients with pancreatic head cancer were included in the study between July 2007 and January 2014.

Preoperative staging

All patients were studied with a dynamic contrast-enhanced Computed Tomography (CT) scan of the abdomen, focusing on the celiac axis and the superior mesenteric vessels. All CT scans were performed on a Somatom helical scanner (Siemens). One hundred and fifty milliliters of nonionic contrast media was injected at a rate of 5 ml/sec, using a power injector. Scans were obtained 20 and 80 s after the injection. Images were reconstructed every 3 mm for the arterial phase and every 5 mm for the portal venous phase.

Patients were also studied with ultrasound. When patients had symptoms of gastric outlet obstruction, radiological and/or endoscopic evaluation was performed.

Diagnostic and therapeutic algorithm

Unresectability criteria were defined according to the National Committee Cancer Network:

- a. Local invasion: unreconstructable occlusion of superior mesenteric/portal vein, greater than 180 degrees superior mesenteric artery encasement or any abutment of the celiac axis, inferior vena cava, or aorta.

- b. Systemic invasion: distant metastasis or presence of ascites due to peritoneal implants.

Ultrasound-guided cytology was performed to all patients with unresectable criteria in order to confirm the diagnosis. Endoscopic or percutaneous palliation was the first choice for patients with metastatic disease and for patients with locally advanced pancreatic cancer with ASA IV or with bad performance status (ECOG > 2). Laparoscopic surgical palliation was indicated for patients with jaundice and locally advanced pancreatic cancer diagnosed in preoperative or intraoperative staging (elective palliation) and also for patients with jaundice with metastatic disease and failure in the endoscopic/percutaneous treatment (necessary palliation). In cases of elective palliation, a laparoscopic double bypass (Roux-en-Y hepaticojejunostomy and gastrojejunostomy) was performed. In cases of necessary palliation with biliary obstruction, only laparoscopic hepaticojejunostomy was performed.

In the postoperative period, length of hospitalization, major and minor complications, and morbidity were analyzed.

Surgical technique

With the patient in supine position, 5 trocars are placed: One umbilical 10-mm trocar incision for the optics, one 10-mm trocar incision for the left hypochondrium, one 10-mm trocar incision between the iliac fossa and the left flank, one 5-mm trocar incision for the right hypochondrium, and another 5-mm trocar incision for the right flank. When the need arises for a hepatic retractor, a sixth 5-mm trocar incision is made in the epigastrium. Work pressure at the pneumoperitoneum was 12 mmHg.

The first surgical move is vesicular hilum dissection and cholecystectomy. Then the biliary hilum is dissected. Afterward, a Roux-en-Y limb is performed. This is done by identifying the angle of Treitz and at approximately 40 cm, the jejunum is severed with mechanical suture. Enter-enterostomy is completed using a second mechanical suture (Fig. 1), creating a 40-cm loop of the jejunum. The jejunum loop is taken toward the biliary tract preferably through the antecolic tract. The transmesocolic tract is used when small intestine loop gets to the biliary tract with too much tension. The biliary duct is then totally or partially cut, depending on whether an end to side or a side to side hepaticojejunostomy is performed (Fig. 2A, B). The hepaticojejunostomy can be performed with absorbable suture with separate stitches or with direct loop stitches. Jejunum enterotomy is performed on the antimesenteric edge, slightly toward the posterior side. Our recommendation is to start suturing from the biliary duct at right angle. Once the biliary anastomosis is finished, the gastrocolic

omentum is opened in order to expose the stomach's posterior side with the small intestine loop placed between the angle of Treitz and the Roux-en-Y limb. The gastrojejunostomy can be a hand-sewn anastomosis or can be performed with stapler (Fig. 3A, B).

Conversion to mini-laparotomy is defined as a ≤ 7 cm incision.

All patients in the series were operated on by the same surgeon.

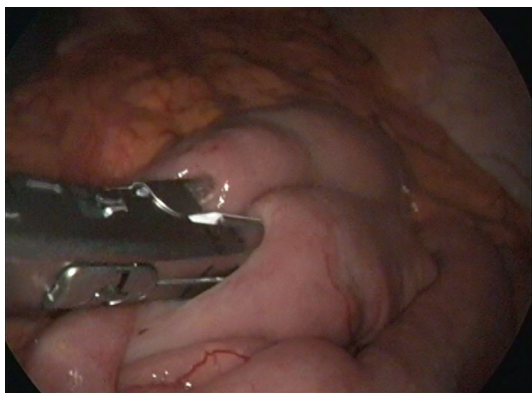


Fig. 1 Entero enterostomy with stapler

Fig. 2 **A** Side to side hepaticojejunostomy. **B** End to side hepaticojejunostomy. *b* bile duct, *j* jejunum

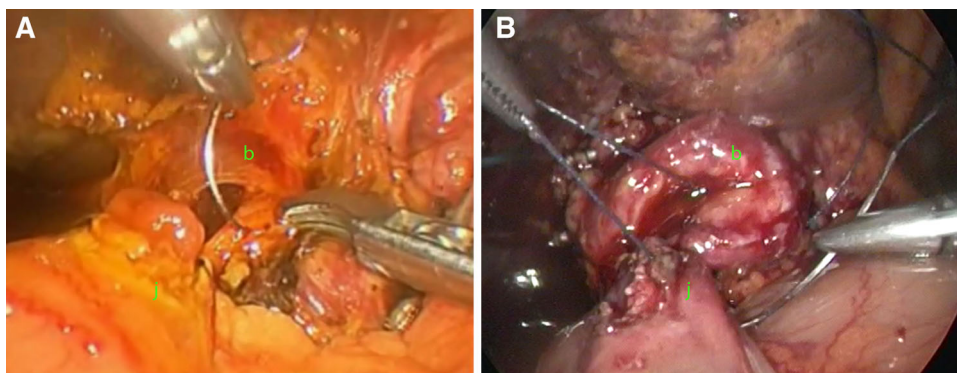
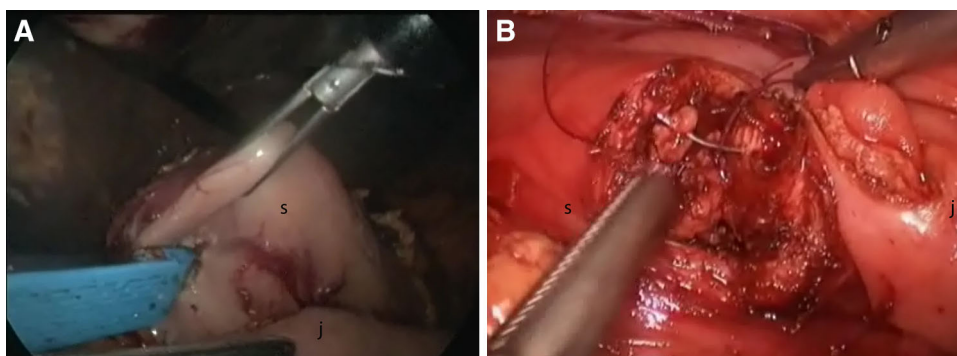


Fig. 3 **A** Gastrojejunostomy with stapler. **B** Hand sewn gastrojejunostomy. *s* stomach, *j* jejunum



Results

Between July 2007 and January 2014, 128 patients with biliary obstruction and unresectability criteria were treated at the Cosme Argerich Hospital (Fig. 4). Eighty-six patients underwent endoscopic/percutaneous drainage because they presented systemic disease and 42 received elective laparoscopic surgical treatment. The endoscopic/percutaneous procedure was successful in 80 patients and failed in six of them, who had to get laparoscopic surgical treatment. A total of 48 patients received laparoscopic surgical palliation: 42 patients, elective palliation and six patients, necessary palliation. The average age was 64 years (range 38–88 years). There were 27 women and 21 men.

The average total bilirubin was 12 Mg/dl ranging from 6 to 20 Mg/dl.

Fourteen out of 42 patients with gastroenteroanastomosis presented symptoms of duodenal obstruction in the preoperative period.

Twelve end-to-side hepaticojejunostomies, 36 side-to-side hepaticojejunostomies, 38 gastrojejunostomies with stapler, and four hand-sewn gastrojejunostomies were performed.

Operative duration was from 120 to 335 min, with an average of 227 min. Surgery duration progressively

Fig. 4 Study flow chart

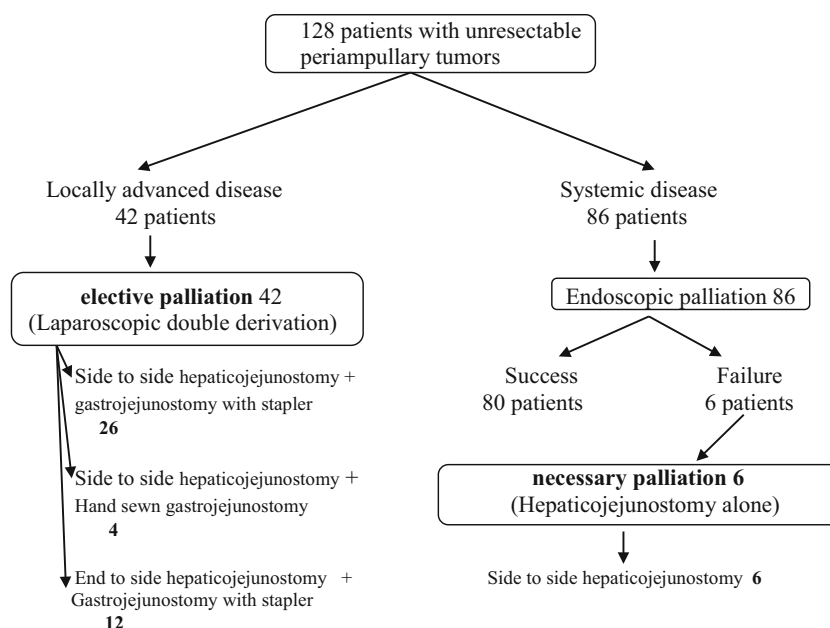


Table 1 Conversions to mini-laparotomies (9 patients)

Causes	No. of patients
Great size of the tumor	3
Increased CO ₂ in blood	4
Bleeding	1
Biliary leak	1

Table 2 Palliative laparoscopic surgery morbidity in 48 patients

Complication	No. of patients
Biliary leakage	7
Intra-luminal gastric bleeding	3
Hemoperitoneum reoperations	2
Abdominal pain reoperations	1
Delayed gastric emptying	2
Pneumonia	1

diminished as an increasing number of procedures were performed.

Nine conversions to mini-laparotomies were performed (18.7 %). Mini-laparotomies were made immediately above the biliary tract in order to minimize the incision length. No patients required a bigger sized laparotomy.

Reasons for conversion to mini-laparotomy are explained in Table 1. Three patients required conversion due to the great size of the tumor, which made anastomosis difficult to perform. Four patients were converted because

of increased CO₂ in blood, one because of intra-abdominal bleeding and another one because of biliary leak after the anastomosis.

Morbidity rate was 33.3 % and it is detailed in Table 2. Seven patients had postoperative biliary leakage. In six patients, biliary leakage was spontaneously healed within 15 days of the postoperative period. One patient required a percutaneous biliary drainage due to a persistent leakage, which eventually resolved. Five out of seven leakages appeared in the first 20 patients of the series.

Three patients had intra-luminal gastric bleeding after gastrojejunostomy performed with stapler. In these three patients, the bleeding was attributable to suture failure. Even though one patient required blood transfusion, the three bleeding episodes were self-limited without the need for upper endoscopy.

Two patients presented hemoperitoneum and had to undergo reoperation. A relaparoscopy was performed in one of them finding a bleeding from the umbilical trocar incision. Other patient who had portal hypertension bled from a variceal peri-choledochal vessel. Patient evolved with multiple organ failure and died on the 7th postoperative day.

One patient required relaparoscopy due to intense abdominal pain. Nevertheless, no pathological findings were identified and this patient evolved without complications. Two patients presented delayed gastric emptying and needed a nasogastric tube for 8 and 10 days, respectively. Both patients presented duodenal obstruction signs in preoperative. Finally, a patient presented right-side pneumonia and received antibiotic therapy as only treatment.

There was no need for late surgeries in any of the patients. Mortality was 2.08 % (one patient) due to intra-abdominal bleeding.

The average hospitalization period was 7.6 days, ranging from 4 to 30 days. The average survival was 11 months, ranging from 3 to 17 months.

Discussion

According to results in this study, laparoscopic surgical palliation is a valid alternative for patients with locally advanced pancreatic cancer. Laparoscopic palliation combines the immediate advantages of mini-invasive methods with the long-term advantages of open surgery with acceptable morbidity rates and low mortality. Surgical palliation through laparotomy lost applicability in recent years due to the advent of endoscopic/percutaneous procedures [7]. These mini-invasive procedures have the advantage of high initial efficacy and short hospital stays. However, the disadvantage of plastic and metallic stents is their durability. Average permeability of plastic stents is 59 days (ranging between 7 and 228 days), while average permeability of metal stents is 128 days (ranging between 111 and 273 days) [5]. Surgical palliation has the advantage of high long-term efficacy, allowing significantly lower readmission rates when compared with endoscopic palliation [6, 7].

As previously mentioned, approximately 80 % of patients with pancreatic cancer have advanced disease not amenable to surgical resection [6, 8]. Survival among patients with metastatic disease ranges between 4 and 7 months according to the different chemotherapy treatments [9, 10]. Furthermore, survival in locally advanced disease, without metastatic disease, reaches from 13 to 21 months depending on different chemotherapy treatments [3]. That is the reason why endoscopic palliation has an unchallenged role in patients with systemic disease. However, locally advanced patients without metastasis also have probabilities of greater than 6-month survival, thus requiring an effective long-term palliation method. Morbimortality in our series shows that laparoscopic palliation is an applicable and effective method, even in patients who required necessary palliation.

To the best of our knowledge, this is the largest series of laparoscopic hepaticojejunostomy and gastrojejunostomy as pancreatic cancer palliation. Most publications on laparoscopic palliation report the use of cholecystojejunostomy as palliation method. This is a simple, easy to perform method; however, it is not applicable to all patients and it has a high failure rate.

Our team deems hepaticojejunostomy to be the surgical method of choice for jaundice palliation. We also consider

that if the patient does not have systemic disease, it is advisable to perform a prophylactic gastrojejunostomy in order to avoid a possible duodenal obstruction. In this study, gastrojejunostomy was not performed in patients with necessary palliation due to short survival expectations and few chances of presenting duodenal obstruction. Nevertheless, the indication for patients with elective palliation can still be discussed. In our experience, the complication of gastrojejunostomy was gastric bleeding representing a 6.25 % morbidity rate, while the probability of duodenal obstruction amounted to 20 % [4].

The main disadvantage of laparoscopic hepaticojejunostomy is its technical difficulty; therefore the learning curve is long and demands a high volume of patients. Surgical duration, postoperative complications, and conversions to mini-laparotomy had strong relation with learning curve, as these were greater in the first 20 patients. Most conversions were due to hypercapnia (as a result of the long surgical duration) and technical difficulties related to the large tumor size, all complications that were solved with increasing training.

The postoperative morbidity of our study series, although similar to that reported in open surgery [7], is mostly explained because of the learning curve. The high number of biliary leaks at the beginning of the experience showed a drawback of the learning curve. However, none of these seven patients had systemic repercussion; six did not need interventions and the last healed with a percutaneous biliary drainage.

This study, although the largest series published so far, still includes a limited number of patients and has a retrospective design. A prospective randomized study evaluating quality of life in patients with non-metastatic locally advanced pancreatic cancer treated with metallic stent or laparoscopic surgery is required.

Conclusion

Surgical laparoscopic palliation is a feasible treatment option for locally advanced pancreatic cancer. Even though metallic stents are still the best palliation method for patients with systemic disease or with prohibitive surgical risk, if stents fail, the laparoscopic approach is a viable treatment.

Disclosures This is an observational study. There are no possible conflicts of interest declared. Authors Gustavo Kohan, Carlos G. Ocampo, Hugo I. Zandalazini, Roberto Klappenbach, Federico Yazzyi, Ornella Ditulio, Carlos Canullán, Juan Alvarez Rodriguez, and Adelina Coturel declare no conflict of interest.

References

1. Siegel R, Naishadham D, Jemal A (2013) Cancer statistics, 2013. *CA Cancer J Clin* 63(1):11–30
2. Hidalgo M (2010) Pancreatic Cancer. *N Engl J Med* 362:1605–1617
3. Lloyd S, Chang BW (2013) A comparison of three treatment strategies for locally advanced and borderline resectable pancreatic cancer. *J Gastrointest Oncol* 4(2):123–130
4. Lillemoe K, Cameron J, Hardacre J et al (1999) Is prophylactic gastrojejunostomy indicated for unresectable periampullary cancer? A prospective randomized trial. *Ann Surg* 230(3):322–328; discussion 328–30
5. Elwir S, Sharzei K, Veith J et al (2013) Biliary stenting in patients with malignant biliary obstruction: comparison of double layer, plastic and metal stents. *Dig Dis Sci* 58:2088–2092
6. Scott E, Garcea G, Doucas H et al (2009) Surgical bypass vs. endoscopic stenting for pancreatic ductal adenocarcinoma. *HPB* 11:118–124
7. Kneuert P, Cunningham S, Cameron J et al (2012) Palliative surgical management of patients with unresectable pancreatic adenocarcinoma: trends and lessons learned from a large, single institution experience. *J Gastrointest Surg* 15(11):1917–1927
8. Buchs N, Addeo P, Bianco F et al (2011) Robotic palliation for unresectable pancreatic cancer and distal cholangiocarcinoma. *Int J Med Robotics Comput Assist Surg* 7:60–65
9. Conroy T, Mitry E (2011) Chimiothérapie de l'adénocarcinome du pancréas métastatique: défis et espoirs (chemotherapy of metastatic pancreatic adenocarcinoma: challenges and encouraging results). *Bull Cancer* 98(12):1439–1446
10. Chauffert B et al (2008) Phase III trial comparing intensive induction chemoradiotherapy (60 Gy, infusional 5-FU and intermittent cisplatin) followed by maintenance gemcitabine with gemcitabine alone for locally advanced unresectable pancreatic cancer. Definitive results of the 2000–01 FFCD/SFRO study. *Ann Oncol* 19(9):1592–1599